Meeting the CHALLENGE

As an avid cyclist, snowboarder and hiker, 53-year old Jan Pendleton is always up for a challenge. Still, she wasn't quite expecting the one that brought her to Lahey's Emergency Room last July.

"I was seeing double and my hand was numb," recalled Pendleton. "I had suffered a stroke the year before and I was concerned I might be having another."

Matthew Tilem, MD, the attending neurologist that evening, remembers the case well. On first examination, he suspected that hypothyroidism—a condition in which the thyroid fails to produce enough thyroid hormone—was causing her symptoms. He consulted with Nicholas Tritos, MD, ScD, a Lahey endocrinologist, who concurred this could be the case.

"Ms. Pendleton told us she had thyroid cancer. Her thyroid had been removed and although she was taking thyroid replacement medication, she had recently stopped taking it because she was scheduled for radioactive iodine treatment at another hospital in the coming days," Tilem explained. "It seemed simple enough, yet, because of her history of stroke at a young age, we wanted to be cautious."

After Pendleton's first stroke, she was found to have a patent foreman ovale (PFO), a congenital anomaly more commonly known as a hole in the heart. In the womb, this hole is necessary to allow efficient circulation of blood and oxygen before the lungs start working. After birth, the hole closes to separate the two upper chambers of the heart, but in one out of every three or four people, the hole remains open. While many people with PFOs never even know they have them, others can have dangerous complications such as strokes.

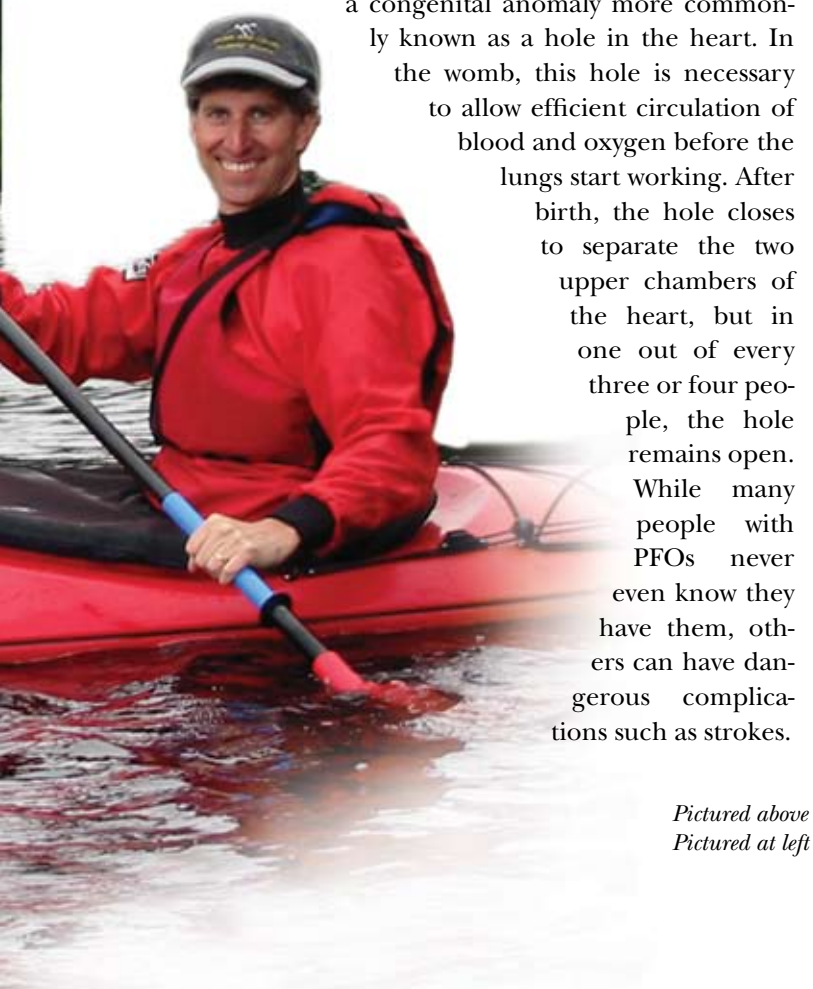

To treat her PFO, Pendleton had a closure device implanted in her heart at another hospital as part of a clinical trial just one month before. That's when she ran into more trouble. Pendleton developed an abnormal heart rhythm, or atrial fibrillation, in reaction to the device. Her doctors then put her on blood thinning medication to prevent her from developing a clot.

"So here's what we had: a patient with stroke-like symptoms who was hypothyroid and who was also on blood thinners—which should actually protect her from having a stroke," said Tilem. "When we did an MRI, we saw that she was having multiple strokes—in both hemispheres—which is an indication of cardioembolic stroke, or stroke caused by the heart. But again, she was on blood thinners, so the risk of this kind of stroke should have been reduced. The question then became: what exactly was going on here?"

Recognizing something very unusual was occurring, Tilem ordered a transesophageal echocardiogram (TEE) to look at Pendleton's heart. The results of the TEE would solve the puzzle and astonish the doctors.

"What we observed from the TEE was that Jan had some sort of tissue-like elements hanging off her closure device and likely traveling to her brain," said Tilem. "We weren't sure what these things were, but they were very worrisome, considering this was someone who had already had a stroke."

Christina Williamson, MD, a cardiothoracic surgeon at Lahey, remembers being called by Tilem to view the TEE results. Around 10 pm, she told Pendleton she would need immediate open heart surgery. By 4 am, Pendleton's device was removed, the hole in her heart repaired.

"One thing I can say about my experience at Lahey is that it truly was a multidisciplinary one," recalled Pendleton. "In a matter of hours, I saw folks from Neurology, Endocrinology, Hematology, Ophthalmology, Cardiology and Cardiac Surgery."

As for her recovery, Pendleton said it went smoothly. "Two and half months after my surgery I was already climbing a mountain with my husband again."

Now that's the kind of challenge Pendleton prefers.

Pictured above left are Christina Williamson, MD, and Matthew Tilem, MD.
Pictured at left are Jan Pendleton and her husband, Steve Kahn.