A Severe Case of Recurrent Coccidioidal Meningitis Complicated by Hydrocephalus

Sarah E. Nelson, MD, and Michal Vytopil, MD. Lahey Clinic Medical Center, Dept. of Neurology

Abstract

Coccidioidomycosis is a fungal infection endemic to the southwestern United States and acquired through inhalation[1]. Coccidioidal meningitis is an unusual and sometimes fatal manifestation of coccidioidomycosis . Recommendations are that patients remain on life-long azole therapy following treatment of their meningitis because relapses can occur[2].

Case Report

53-year-old female with history of hepatitis C, hepatocellular carcinoma, and coccidioidal meningitis presented four months after discontinuing her chronic suppressive fluconazole following normal CT head and CSF evaluation. She had been intermittently confused and required assistance with ambulation , presenting with a fall.

CT head 11/14/11

CT head 3/2/12

Exam:

•Afebrile. Otherwise vitals stable.

•A&Ox1.Followed commands, named objects, repeated phrases. Cranial nerves intact except for fast beating rightward, leftward, and downward nystagmus. Funduscopic exam not well visualized. Motor, sensation, and cerebellar exams unremarkable. Reflexes symmetric with toes down. Gait exam initially deferred.

Imaging:

•CT head: increased ventricle size since CT head in November 2011.

•MRI brain with/without contrast: severe meningitis with extensive bilateral edema in the brain parenchyma.

Laboratory Tests:

•BMP: low-normal sodium. CBC: normal .

•CSF: 273 WBC, 6150 RBC, 52% neutrophils, 33% lymphocytes, 1% monohistiocytes, 14% abnormal lymphoplasmacytoid lymphocytes, 28 glucose, 300 protein.

FLAIR 3/2/12

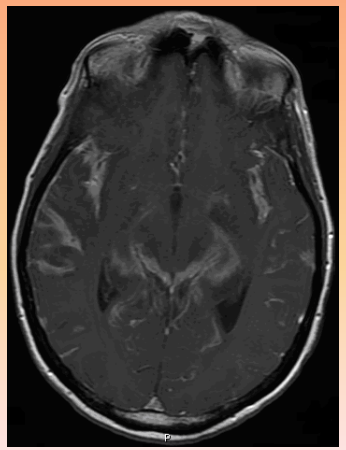

T1+con 3/2/12

Hospital Course:

•Started on empiric fluconazole for presumed recurrent coccidioidal meningitis.

•Lab tests eventually showed positive coccidioides antibody in the serum.

•Follow up CT head demonstrated stable hydrocephalus.

•Patient's cognition improved.

•Discharged in stable condition to rehabilitation.

Summary

Coccioidal meningitis is a serious complication of coccidioidymyocisis that is well treated with azole medications. It is recommended that patients remain on life-long therapy due to the possibility of recurrence. Our case underscores the need for chronic suppressive azole therapy to prevent relapses of coccidioidal meningitis.

References

[1]Galgiani , J.N.. *West J Med*. 1993;159:153-171.

[2]Dewsnup et al. *Ann Intern Med*. 1996;124:305-310.