Parkinsonism after Hymenoptera Sting

Lahey Hospital & Medical Center

Diana Apetauerova, MD & Mathew Alias, DO

Lahey Hospital & Medical Center, Burlington, MA

ABSTRACT

OBJECTIVE: Hymenoptera stings are an unusual cause of neurologic sequela. We describe a rare case of several hymenoptera stings causing parkinsonism.
BACKGROUND: Factors involved in parkinsonism include exposure to agrochemicals, heavy metals, solvents, and MPTP. Hymenoptera stings rarely cause neurologic dysfunction, but have reported to have caused parkinsonism in previous case reports. Treatments described in the studies show mixed response to levodopa, but positive response to plasmapheresis followed by monthly intravenous immunoglobulin infusion.
DESIGN/METHODS:
A case from the Movement Disorders Clinic at the Lahey Clinic is reviewed, with clinical presentation, imaging studies, and clinical course reviewed.
RESULTS:
The patient is a 48 year old gentleman, who presented to a neurologist six months after being stung on the face by 25 honeybees. Immediately after the stings, the patient went to the emergency department, where he was treated for facial swelling with diphenylhydramine. One week later, the patient developed left arm tremor. He gradually developed stiffness, and loss of both strength and dexterity. The patient worked as a cemetery worker, and had difficulty completing his assignments, and presented to a neurologist approximately six months later. On examination, he had slowed horizontal saccades, hypophonic speech, and predominantly left-sided akinetic rigid syndrome. The left upper extremity had moderate resting, postural, and action tremor, with mild postural tremor in the right upper extremity. There was no right sided bradykinesia or right sided rigidity. An MRI of the brain was unremarkable. SPECT dopamine transporter imaging showed markedly reduced uptake in bilateral putamen. The patient responded poorly to levodopa.
CONCLUSIONS:
Extrapyramidal disease is an extremely uncommon complication of Hymenoptera stings. An immune-mediated delayed hypersensitivity is the suspected cause of this reaction. Response to aggressive treatment with immunosuppressant agents has been described.

INTRODUCTION

Parkinsonism is clinical syndrome that is characterized by bradykinesia, rigidity, tremor and postural instability. The most common cause is Parkinson's disease . Secondary causes of parkinsonism that produce a similar clinical phenotype.vary, including infection, prion diseases, vascular disease, trauma, toxic exposures to agrochemicals, heavy metals, solvents, and MPTP. The clinical response of parkinsonian symptoms caused by secondary parkinsonism is often not as robust as that seen in classic Parkinson's disease. These aberrant causes of parkinsonism may be a valuable tool in research, as was the case with MPTP, into the pathophysiology of Parkinson's disease and treatment.

Toxic causes of parkinsonisms include 1-methyl-4-phenyl-1,2,3,6-tetrahdyropyridine (MPTP), carbon monoxide exposure in both an acute and delayed-relapsing setting, and methanol. Heavy metals that may cause parkinsonian features include manganese, iron, and copper. Still rarer causes of parkinsonisms include brain tumors, paraneoplastic disease of the substantia nigra, and several genetic conditions, such as Gaucher's disease, and mutations to genes such as LRRK2, PARK2, PARK7, PINK1, and DJ1.

CASE

The patient is a 48 year old right handed gentleman, who reported onset of tremor approximately 6 months prior to presentation. He had been stung by approximately 25 bees on the right side of the face. He had significant swelling and went to ER, received diphenylhydramine which improved the swelling. Approximately 1 week after this incident, he developed left hand tremor. This gradually got worse over the course of 5 months, as he also began to notice weakness, stiffness, and loss of dexterity, particularly on the left side. His occupation in a cemetery required significant physical labor and he began having difficulty completing physical assignments, with no cognitive changes. Past medical history was remarkable for depression for about 3 years, with recent worsening but no suicidal ideation.
Physical examination at presentation: Middle aged gentleman with no acute distress.
General examination and cranial nerve examinations were unremarkable with extraocular movements being full, no nystagmus. On motor exam he had full strength on the right side, but he had the slight weakness in the upper motor neuron pattern on the left side, including the deltoids, finger extensors, iliopsoas which were 5 minus out of 5. Reflexes were symmetric and plantar response was flexor bilaterally. Sensory exam and cerebellar exam were intact.
Movement disorders examination: Remarkable for prominent facial masking, he had slow saccades in the horizontal gaze, no square wave jerks, speech is slightly hypophonic. There were slow tongue movements. UPDRS scores revealed left sided predominant signs. Rigidity was scored 3 on the left side and 2 in the neck. The patient had a mild postural and resting tremor on the left. Left sided resting tremor rated as 2, postural and action as 2. He had no tremor in the left lower extremity. He has mild postural tremor in the right hand rated as one. He had no bradykinesia or rigidity on the right. Bradykinesia on the left side was rated as 2 on finger taps, pronation supination scored a 3, opening closing fist rated a 3, and foot tapping scored a 3. He was able to standup using both hands and walked with a typical flexed posture. There was diminished arm swing on the left side, visible tremor, shorter steps especially with turns. Postural stability was intact to retropulsion testing.

Clinical Course: A brain MRI was ordered by his primary care physician 3 months after the incident, and was relatively normal for his age. Dopamine transporter studies (DaT) scan was performed and showed a dopaminergic deficiency in bilateral putamina. On follow up visit, the patient said that he continued to feel very clumsy and weak on his left side. He had a fall at work resulting in a fractured left wrist. The patient did not show a clear response to levodopa at 400 mg divided during the day, with no signficant changes with a late or missed a dose. At the dose of 800 mg, there was mild improvement on examination with less rigidity and bradykinesia on the left but subjectively, patients did not feel a difference. UPDRS motor scores improved from 28 to 18. Trials of both trihexyphenidyl, 1mg twice daily, and prednisone 60 mg taper over 4 week period did not result in any significant improvement. Rasagiline 0.5 mg was started. He continued to have difficulties at work, specifically using the electrical saw and other heavy equipment, with a fear of further injury. He no longer felt safe to operate the heavy machinery because of left sided parkinsonism.

Figure 1: MRI of brain

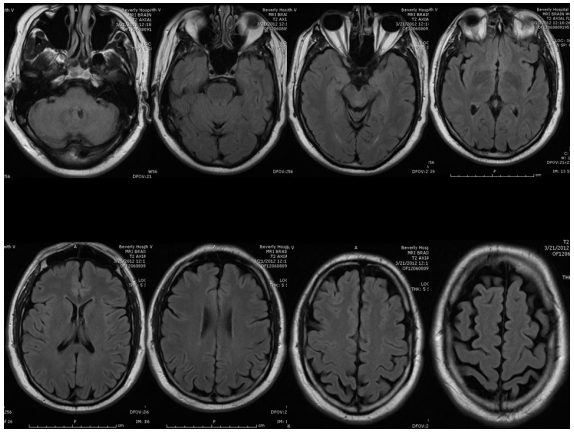

Figure 2: . Dopamine transporter Scan showing dopaminergic deficiency in bilateral putamina

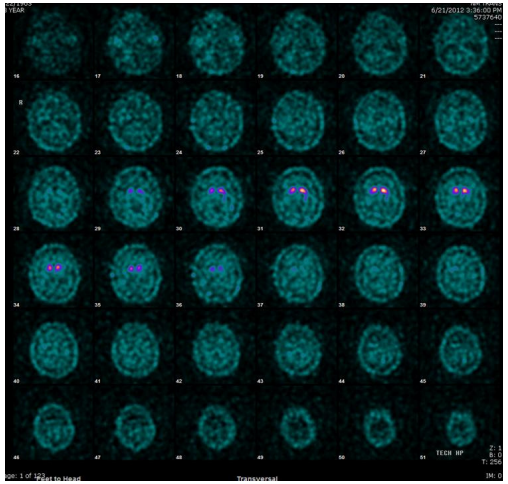

DISCUSSION

Systemic manifestations of hymenoptera stings are a rare complication, with neurologic manifestations extremely rare. Case reports of cerebral infarction, optic neuropathy, encephalopathy, and myeloradiculopathy have all been reported.[1-8] There have been few reported cases of basal ganglia involvement after hymenoptera sting. In a majority of these studies, the response to dopaminergics, anticholinergics, and amantadine has been poor. In our patient, the response to typical dopaminergic medications was mild, with minimal symptomatic response to trihexyphenidyl. This rapid progresssion and mild response to typical pharmacologic treatment may be suggestive of a unique pathogenesis.

Our study was unique in two respects. This was the first study using dopamine transporter imaging, and in this patient, was consistent with a dopaminergic deficiency. This patient also had a significant burden of venom, as he was stung by approximately 24 bees, far greater than those in previously published studies.

Leopold and colleagues suggested an immunological etiology, with a description of a positive response to plasmapheresis, followed by monthly infusions of intravenous immunoglobulin G with three times a day azathioprine. This resulted in an improvement in the UPDRS motor score decreasing from 56 to 39.[1] The basis for treating with these agents was based on SPECT imaging findings and nonspecific CSF markers. A comprehensive randomized, double blinded, controlled study has yet to be completed for parkinsonism caused by hymenoptera sting, most likely due to its unusually low incidence. Conversely, more recently studies have been done to study the use of bee venom in the treatment of MPTP induced Parkinson'sdisease.[9,10]

REFERENCES

1. Leopold, N. A., Bara-Jimenez, W. and Hallett, M. (1999), Parkinsonism after a wasp sting. Mov. Disord., 14: 122–127.
2. Gale AN. Insect-sting encephalopathy. BMJ 1982;284:20–21.
3. Bogolepov NK, Luzhetskaya TA, Fedin AI, Artomasova AV, Vasil'ev PN, Grigorexskaya NG. Allergic encephalomyelo-polyradiculoneuritis from a wasp sting (clinico-pathologic report). Zh Nevropatol Psikhiatr Im S S Korsakova 1978;78:187–191.
4. Gallego J, Tunon T, Soriano G, Delgado G, Lacruz F, Villanueva JA. Bilateral pallidostriatal necrosis caused by a wasp sting: a clinical and pathological study. J Neurol Neurosurg Psychiatry 1995;58:474–476.
5. LaPlane D, Widlocher D, Pillon B, Baulac M, Binoux F. Comportment compulsif d'allure obsessionelle par necrose circonscrite bilaterale pallido-striatale. Encephalopathic par piqure de guepe. Rev Neurol (Paris) 1981;137:269–276.
6. Agarwal V, Singh R, Chauhan S, D'Cruz S, Thakur R. Parkinsonism following a honeybee sting. Indian J Med Sci. 2006 Jan;60(1):24-5.
7. Mittal R, Munjal S, Khurana D, Gupta A.Parkinsonism following Bee Sting: A Case Report.Case Rep Neurol Med. 2012;2012:476523. doi: 10.1155/2012/476523. Epub 2012 Oct 10.
8. Franco E, Casado JL, Robledo A, López-Domínguez JM, Blanco A, Díaz-Espejo C.Bilateral striatal necrosis following a wasp sting.Rev Neurol. 2000 Nov 16-30;31(10):997-8.
9. Kim JI, Yang EJ, Lee MS, Kim YS, Huh Y, Cho IH, Kang S, Koh HK.Bee venom reduces neuroinflammation in the MPTP-induced model of Parkinson's disease. Int J Neurosci. 2011 Apr;121(4):209-17. Epub 2011 Jan 26.
10. Chung ES, Kim H, Lee G, Park S, Kim H, Bae H.Neuro-protective effects of bee venom by suppression of neuroinflammatory responses in a mouse model of Parkinson's disease: role of regulatory T cells. Brain Behav Immun. 2012 Nov;26(8):1322-30. Epub 2012 Sep 5.