Sporadic Creutzfeldt-Jakob Disease Presenting with Fixed Focal Dystonia

Lahey Hospital & Medical Center

Mathew Alias DO, Brian J Scott MD & Diana Apetauerova MD

Lahey Hospital & Medical Center, Burlington, MA

ABSTRACT

OBJECTIVE - A wide spectrum of neurologic symptoms occurs during the course of prion disease. We describe a unique case of dystonia being the presenting feature in sporadic Creutzfeldt-Jakob disease.

BACKGROUND - Sporadic Creutzfeldt-Jakob disease is a rare neurodegenerative disease, with many clinical presentations. Rapidly progressive dementia is a main clinical symptom, and movement disorders, specifically myoclonus and gait disturbance, typically occur later in disease.

DESIGN/METHODS
A case from the Movement Disorders Clinic at the Lahey Hospital & Medical Center is reviewed, with clinical presentation, imaging studies, electroencephalogram, laboratory results, and clinical course reviewed.

RESULTS
A 64 year old right handed woman presented to the Movement Disorder Clinic with subacute, progressive focal, fixed dystonia of the right hand. She first noticed diminished sensation in the 4th and 5th digits eight weeks prior to presentation, and later developed cramping and involuntary flexion of the fingers and her hand. There was a high amplitude, jerky, irregular action tremor. An EMG of the upper extremity was performed on two separate occasions, and was found to be normal. Brain and cervical MRI were unremarkable. A brain SPECT scan showed moderate asymmetric decreased perfusion to the right globus pallidus, and small focal perfusion defects involving the left high frontal and parietal-occipital cortices. EEG showed moderate encephalopathy with excessive bifrontal theta and delta activity. Initial lumbar puncture results were normal, but protein 14-3-3 later returned positive. The patient's mental status rapidly deteriorated over two months, and she discharged home with hospice care. She died three months later, less than seven months from symptom onset.

CONCLUSIONS
Movement disorders are unusual presenting symptoms of CJD. Of these, fixed dystonia is rare, with one case previously reported. In the majority of cases, dystonia is associated with other movement disorders, such as focal jerk myoclonus, choreoathetoid movements, postural tremor, alien limb, or bradykinesia.

INTRODUCTION

Sporadic Creutzfeldt-Jakob disease is a rare neurodegenerative disease that presents with a rapidly progressive dementia as an initial clinical symptom[1]. This is combined with findings of a minimum of two of the four additional symptoms of myoclonus, visual or cerebellar disturbances, pyramidal or other extrapyramidal dysfunction, and akinetic mutism[1]. Symptoms, however may be variable and include a broad spectrum of movement disorders[1]. Movement Disorders and focal sensory complaints are rarely the presenting complaint in CJD, although the majority of patients develop myoclonus and extrapyramidal as the disease progresses.

We describe a patient who presented with a fixed focal hand dystonia accompanied by features of a complex regional pain syndrome (CRPS) in the right upper extremity. Her subsequent clinical course and ancillary studies were consistent with probable CJD. This case raises questions about the mechanism by which dystonia and CRPS may coincide, and it highlights a distinctly unusual presentation of prion disease.

CASE

A 64 year-old woman, who as a professional writer, presented to movement disorder clinic with a subacute, progressive, focal dystonia of the right hand. Two months prior, she noticed diminished sensation in the fourth and fifth digits, followed by cramping and involuntary flexion of the fingers, to the point that she could no longer open her hand with other extremities uninvolved. Her medical history was significant for osteoporosis. At the time of presentation, she took no medications and her family history included a brother with spasmodic dysphonia.

Physical examination: Gross inspection revealed that the right hand was markedly swollen, with a patchy reddish, purple discoloration on the dorsal aspect, as well as allodynia and dysesthesia in the right hand and forearm. Her mental status examination was normal. Her neurological examination revealed a fixed flexion dystonia of the right hand, most prominent in the fourth and fifth fingers and to a lesser degree in the second and third. She identified no sensory tricks that would allow her to open her hand. A high amplitude irregular tremor was seen, especially when she reached for objects. Her strength could not be fully tested in the right hand and wrist due to pain, but was otherwise full throughout. She had reflex asymmetry, with hyperreflexia in the biceps, brachioradialis and patellar reflexes on the right, and normal reflexes on the left side. Plantar responses were downgoing bilaterally. Impaired graphesthesia and diminished sharp/dull discrimination were present in the right hand. Her gait was normal.

Clinical Course: Treatment trials of klonopin, botulinum A toxin injections, oxycodone, and gabapentin resulted in marginal improvement. Serum testing of anti-nuclear antibodies, lupus anticoagulant, anti-cardiolipin antibodies, Lyme antigen, C-reactive protein, serum copper and routine chemistries were normal. In the weeks prior to presentation to the Movement Disorders Clinic, two electromyography and nerve conduction studies (EMG/NCS) of the upper extremity were completed, and both studies were normal. A brain MRI and head/neck MRA were unremarkable. A cervical spine MRI showed foraminal stenosis on the right at C5-6 and C6-7. Cerebrospinal fluid (CSF) was acellular with a protein of 37 and a glucose of 70. CSF cytology and paraneoplastic antibodies were negative. The 14-3-3 protein was found elevated in the CSF. A Tc 99 brain SPECT scan showed patchy decreased perfusion throughout the cortex bilaterally and moderately decreased perfusion in the globus pallidus, right greater than left (FIG 1 – SPECT). An EEG showed delta and theta spikes predominantly in the left anterior leads. Prompt treatment with anticonvulsants resulted in no clinical improvement. Over the next month, the patient's condition declined rapidly. She developed myoclonus, first on the right side and then in all four extremities. She complained of memory loss, dysphagia, imbalance and word-finding difficulties. The patient developed marked dysarthria and an expressive aphasia, and later was unable to walk due to ataxia and was therefore admitted to the hospital. Weeks later, repeat MRI showed volume loss compared to the previous study, with new areas of cortical restricted diffusion, most pronounced in the left fronto-parietal hemisphere and in bilateral caudate nuclei and putamina (FIG 2 - MRI). A repeat EEG showed bifrontal theta and delta activity left greater than right with no spikes or sharp waves. The patient returned home with hospice care and died three months later, less than seven months from the onset of her illness.

Figure 1: SPECT Scan images demonstrate moderate asymmetric decreased perfusion to the right globus pallidus as compared to the left. There are also small focal perfusion defects involving the left high frontal, and left parietal, parieto-occipital cortices

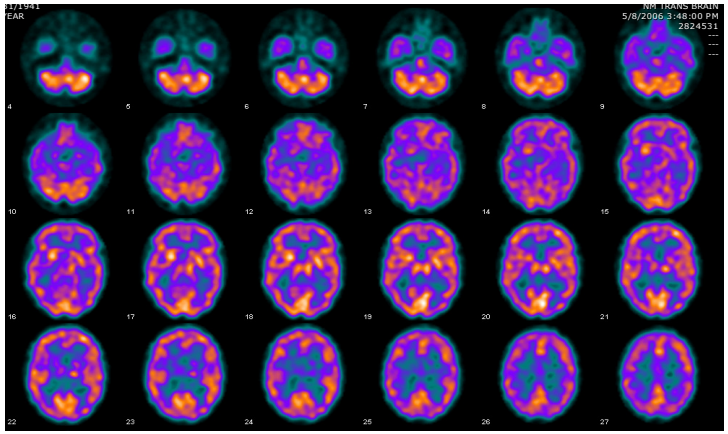

Figure 2: There is development of restricted diffusion within bilateral striatum, caudatolenticular bridges, left parietal cortex involvement of the left > right cingulate cortex.

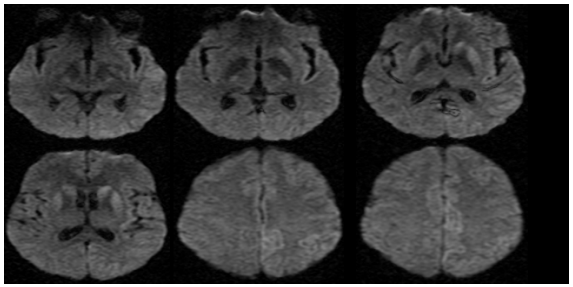

DISCUSSION

Movement disorders as a presenting symptom for CJD are rare, as only 1 in 230 cases described by Brown and colleagues had presentation as a movement disorder.[2] The most common movement disorders in CJD patients at presentation include myoclonus (80%), gait disturbances (80%), and cerebellar ataxias (77%)[1]. Focal dystonia had previously been reported in cases of sporadic or familial CJD[3,4], as well as variant CJD.[5] Types of dystonia described include blepharospasm, focal hand dystonia, truncal dystonia and neck dystonia.

This case was characterized by focal hand dystonia as a presenting feature accompanied by severe pain, allodynia and trophic changes that were clinically consistent with a complex regional pain syndrome similar to the 'Causalgia-dystonia syndrome'[6]. The syndrome affects predominantly adult women, and is usually post-traumatic and typically began in one extremity. The pain precedes or coincides with the onset of dystonia, and the patients studied all described an acute, focal onset of dysfunction followed by spread. The disease course of patients with causalgia-dystonia syndrome was not progressive, and none developed cognitive impairment, gait ataxia or myoclonus.

In this case, the SPECT abnormalities correlated well with the EEG findings, and preceded the development of characteristic diffusion-weighted MRI changes by several weeks. The normal EMG/NCS support a CNS localization involving cerebral cortex or basal ganglia. The skin changes and pain suggestive of CRPS are seen following trauma, and often attributed to peripheral or autonomic dysregulation. The pathophysiology in this case would suggest a potential central etiology for the CRPS, or the development of CRPS as a consequence of the dystonia. Asymmetric extrapyramidal symptoms/signs have been described in CJD, as patients may present with a corticobasal syndrome (CBS)[7]. In a recent review of the Austrailian National Creutzfeldt Jakob Disease Registry, sCJD-CBS accounts for 1.8% of all CJD cases. The study describes the most common presentations of sCJD with CBS involving limb apraxia (70%) and alien limb phenomena (85%) being the most common presenting forms. The most common movement disorders were myoclonus (80%) and dystonia (45%)[8], but these were not necessarily the presenting features of CJD. In a majority of cases, dystonia is associated with focal jerk myoclonus restricted to the dystonic limb, choreoathetotic movements, postural tremor, alien limb, or bradykinesia. Generalized dystonia has been more commonly reported at later stages of the disease, but is often preceded by focal or hemidystonia.

REFERENCES

1. Edler J, Mollenhauer B, Heinemann U, Varges D, Werner C, Zerr I, Schulz-Schaeffer WJ. Movement disturbances in the differential diagnosis of Creutzfeldt-Jakob disease. *Mov Disord.* 2009 Feb 15;24(3):350-6.
2. Brown P, Cathala F, Raubertas RF, Gajdusek DC, Castaigne P. The epidemiology of Creutzfeldt-Jakob disease: conclusion of a 15 year investigation in France and review of the world literature. *Neurology.* 1987 Jun;37(6):895-904.
3. Marchiori PE, Yasuda N, Azevedo HC, et al. Creutzfeldt-jakob disease. A survey of 14 patients. *Arq Neuropsiquiatr.* 1996;54(4):577-583.
4. Hellmann MA, Melamed E. Focal dystonia as the presenting sign in Creutzfeldt-Jakob disease. Mov Disord. 2002 Sep;17(5):1097-8.
5. Heath CA, Cooper SA, Murray K, Lowman A, Henry C, MacLeod MA, Stewart G, Zeidler M, McKenzie JM, Knight RS, Will RG. Diagnosing variant Creutzfeldt-Jakob disease: a retrospective analysis of the first 150 cases in the UK. *J Neurol Neurosurg Psychiatry.* 2011 Jun;82(6):646-51.
6. Bhatia KP, Bhatt MH, Marsden CD. The causalgia-dystonia syndrome. *Brain.* 1993;116 (Pt 4)(Pt 4):843-851.
7. Wu HM, Lu CS, Huang CC, Lyu RK, Chen RS, Wu YR, Chen YC, Lai SC, Hung J, Tsai YT, Toh CH, Kuo HC. Asymmetric involvement in sporadic Creutzfeldt-Jakob disease: clinical, brain imaging, and electroencephalographic studies. *Eur Neurol.* 2010;64(2):74-9.
8. Lee W, Simpson M, Ling H, McLean C, Collins S, Williams DR. Characterising the uncommon corticobasal syndrome presentation of sporadic Creutzfeldt-Jakob disease. *Parkinsonism Relat Disord.* 2013 Jan;19(1):81-5. Epub 2012 Sep 1.